

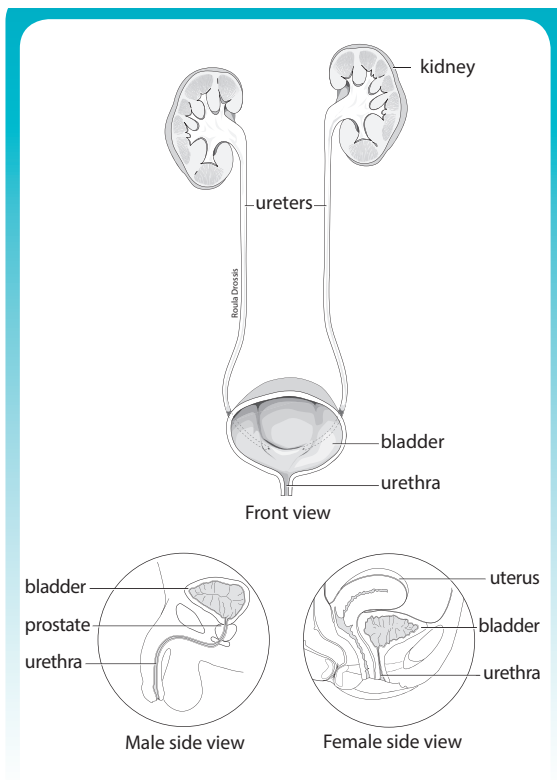


Hematuria

Blood in the urine is a common problem which requires assessment by your physician.

The medical term for blood in the urine is **hematuria**. When the blood is visible it is referred to as **gross hematuria**. In most patients with hematuria, the blood is only visible under the microscope, and therefore is called **microscopic hematuria**.

Blood may enter the urine anywhere along the urinary system, from the kidneys to the bladder outlet. Your kidneys filter blood to eliminate waste products and excess water which are excreted in the urine. The urine drains from each kidney into a ureter, a long narrow tube that conducts urine to the bladder. The bladder then expels urine through the urethra (in a woman) or through the prostate and urethra (in a man).



Microscopic hematuria can be an early sign of an abnormality in the urinary tract and investigation is often recommended. Gross hematuria suggests a higher likelihood that some disorder is present and further testing is necessary. In many cases however, investigations do not uncover an obvious source for very small amounts of blood detected in the urine.

Hematuria may be an early indication of damage or injury to the kidney(s). In some, heavy exercise can cause blood to leak into the urine. Blood in the urine is often found in those with a urinary infection or stone. Men who have an enlarged prostate (benign prostatic hyperplasia, BPH) are sometimes found to have blood in the urine.

Hematuria may be a sign of a tumour in the urinary system. For example, bladder tumours are often first identified when blood is seen in the urine. Kidney tumours generally occur between the ages of 50 and 70 years and may grow slowly without producing any symptoms until it reveals itself with blood in the urine. Prostate cancer, although common in older men, rarely leads to urinary bleeding.

Your doctor will suggest investigations to identify a source for your hematuria depending on many factors including your age, past medical history, smoking history, current voiding pattern and characteristics of your urinary bleeding. Stopping smoking will greatly reduce your chances of bladder cancer.

Tests of the urine and blood

A simple office urine dipstick test is often the first step in investigating hematuria. Microscopic examination of the urine will confirm the presence of blood and quantify the amount. Urine may be tested on a number of separate occasions to determine if microscopic hematuria is consistently present. Pus cells in the urine may suggest the presence of infection. Urinary protein may indicate kidney malfunction as a source for hematuria.

Hematuria

A **urine culture** may be performed if a urinary infection is suspected. Cells which are normally shed in the urine can be examined microscopically (**urine cytology**). Occasionally, the appearance of these cells will suggest the possibility of a tumour growing in the lining of the urinary system. If such cells are found, the source must be identified.

Other blood and urine tests may be added to further assess the cause of hematuria.

Imaging studies

Examination of the kidneys is often an important part of the investigation of hematuria. Imaging studies are used to “see” the details of kidney anatomy.

Ultrasound can examine the kidneys painlessly with sound waves. **Intravenous pyelography (IVP)** in which a contrast “dye” is injected intravenously and excreted by the kidneys will clarify the kidney drainage system anatomy. A **CT scan** or **MRI** will give a more detailed view of the kidneys. Your doctor will determine which imaging study is most appropriate for your circumstances.

Cystoscopy

Although imaging studies are very accurate in detecting major problems in the kidneys, such as tumours or stones, they are not as useful at examining the bladder and its outlet. For this reason, a minor outpatient procedure called a **cystoscopy** is often recommended to complete your investigation.

Cystoscopy involves passing a thin “scope” through the urinary tube (urethra) into the bladder to visually inspect the lower urinary system. Sometimes an x-ray of the kidneys is performed at the same time. The procedure generally takes only a few minutes, usually with minimal discomfort. Cystoscopy will reliably identify a bladder tumour. Cystoscopy may be omitted in most children and young healthy adults in whom the likelihood of bladder tumours is very low.

In many patients, especially those with microscopic hematuria, a specific cause of blood in the urine is not found. If all of the examinations including urine tests, imaging studies of the kidneys and cystoscopy are normal, the risk of having a serious underlying condition is extremely low. Follow-up through your family physician can ensure that any changes are identified promptly.

If visible urinary bleeding recurs, these tests may need to be repeated. Additional tests may be requested, including specialized imaging of the kidneys or their blood vessels and visual inspection of the kidney drainage systems.

Even if assessment is required, the common problem of microscopic hematuria in men and women is often not related to any significant problem. In some people, a few blood cells leak through the filter of the kidney into the urine, but there is no abnormality present. Gross hematuria suggests a much higher likelihood that some disorder is present.

This publication is produced by

Canadian **U**rological Association
The Voice of Urology in Canada



Association des **U**rologues du Canada
La voix de l'urologie au Canada

The information in the publication is not intended to convey medical advice or to substitute for direct consultation with a qualified medical practitioner. The Canadian Urological Association disclaims all liability and legal responsibility howsoever caused, including negligence, for the information contained in or referenced by this brochure.

© 2014, Canadian Urological Association. All rights reserved.

cua.org